ULTRASOUND FOR THE GALLBLADDER: The How-To Guide

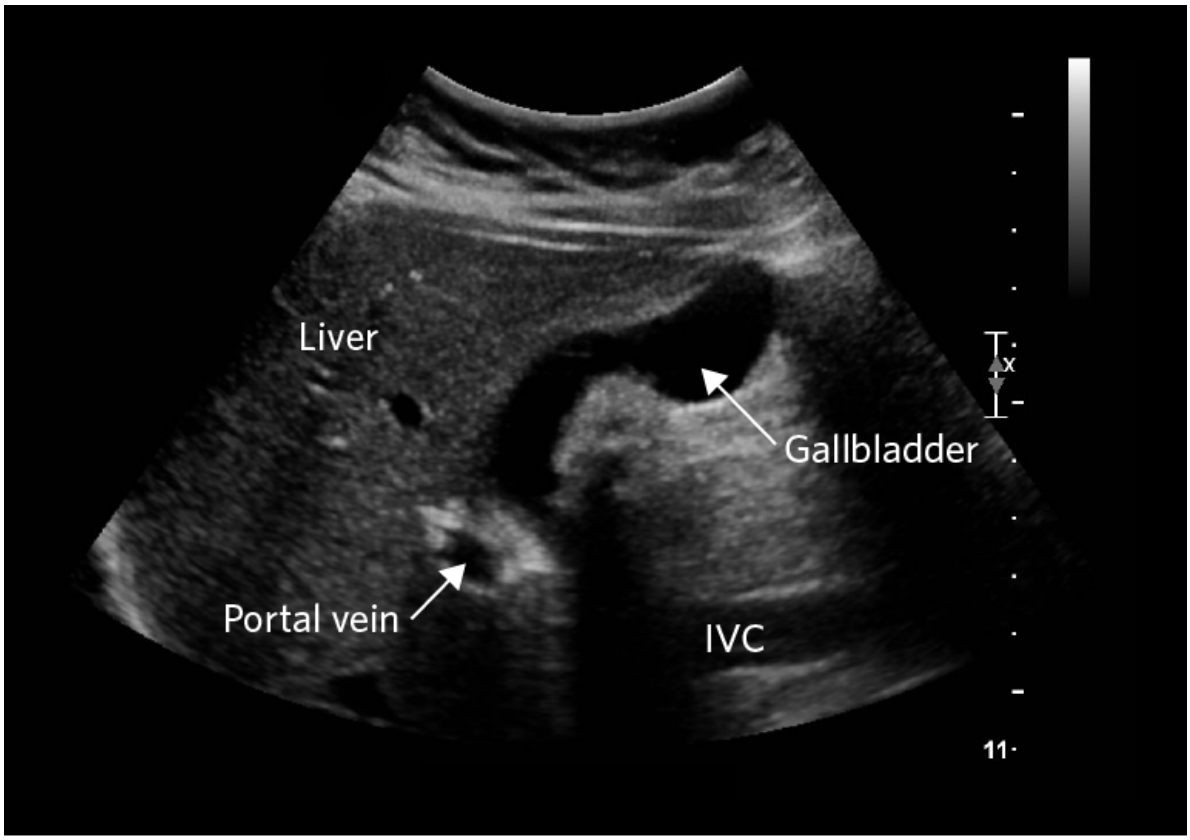

How to do it:

1. Patient is in the supine position, or left lateral decubitus position.
2. Hold abdominal probe (low-frequency curved probe) with indicator towards patient's head, just below the xiphoid process.
3. Angle the probe so that the liver is seen in the upper left part of the screen.
4. Slide the probe to the patients right (laterally) and identify your landmark, the portal vein.
5. From the portal vein, follow the inter-lobar fissure until you locate the gallbladder, which is generally obvious from its bulbous shape and large size. You may need to rotate the probe slightly clockwise or counter-clockwise.
6. Confirm that this is the gallbladder (GB) by finding the exclamation point sign (the gallbladder body, tapering to the neck of the GB, then the inter-lobar fissure and the portal triad look somewhat like an exclamation point).

7. Sweep through the GB in both its long and short axis, looking for stones (bright echogenic round structures with a dark shadow behind them).

8. Sweep again, looking for signs of cholecystitis. The presence of gallstones means the patient has cholelithiasis; other findings and your clinical judgment determine if they have cholecystitis. Positive findings of cholecystitis include:

    - a sonographic Murphy's sign,
    - anterior GB wall thickness (measured in the short axis) of more than 3 mm,
    - and pericholecystic fluid (free fluid around the gallbladder).

How to do it better:

- Placing the patient in the left lateral decubitus position will improve your images most of the time.
- High-riding GBs are sometimes difficult to find, and require you to scan between the ribs to view the gallbladder.
- Having the patient take in a big breath and hold it brings the GB down (more caudal) and can help to view a high-riding GB.
- To help differentiate the GB from a vessel (like the IVC or portal vein) use colour Doppler to confirm that there is no flow in the "sac".
- Ensure they haven't had their GB removed; otherwise you'll waste a lot of time!
- If you still can't find to gallbladder, ask if your patient has recently eaten – this will contract the gallbladder and make it difficult to find.
- Since this can be an uncomfortable exam, don't hesitate to give analgesics. You will then be able to gently push in the RUQ and generate a better image.

How to do it safely:

False Positive Findings:

a) GB wall thickness can be increased in the following states:

    - Acute cholecystitis
    - Chronic cholecystitis
    - Cirrhosis and other causes of ascites
    - Viral hepatitis
    - CHF
    - Hypoalbuminenia
    - Chronic renal failure
    - HIV
    - Pancreatitis
    - Contracted GB (non-fasting state)

b) Polyps/malignancy in GB – can look like stones, but usually the shadows aren't as dark, and they aren't mobile (i.e. don't move around as you move the patient from left to right lateral decubitus).

c) Edge artifact can make the GB wall appear thickened, thus only measure the GB wall thickness anteriorly in the short axis (where it looks round).

d) Sludge in the GB can be mistaken for stones, but more commonly, artifact can look like sludge; artifact will disappear with probe movement and sludge will not.

False Negative Findings:

a) Acalculous cholecystitis – though rare, the mortality is relatively high as it usually occurs in critically ill patients. All tests perform poorly for this disease. If you suspect it, consult a surgeon regardless of the ultrasound findings.

b) Wall-Echo-Shadow Sign (WES-sign) – occurs when stones entirely fill the lumen of the GB, obliterating the GB wall that is your landmark. The WES sign is characterized by the echogenic gallbladder WALL, the more ECHOgenic gallstone, and the large SHADOW from the stone. This can be misinterpreted as bowel.

c) A gangrenous GB will have air in the GB wall lumen, thus distorting the US waves, and making it difficult to visualize the GB.

d) A stone in the neck of the GB is easy to miss if the neck is not properly visualized.

e) Small stones might be missed. Consider scanning the patient in 2 or 3 different positions to visualize the GB better.

f) Choledocholithiasis may only be confirmed by the finding of a dilated common bile duct. So a normal appearing GB on POCUS will not rule this out.

How to use this in practice:

Gallbladder disease covers a spectrum of disease states from asymptomatic cholelithiasis to acute cholecystitis with potential lab abnormalities, fever, and longer lasting symptoms.

No single clinical or laboratory finding has a sufficient positive or negative likelihood ratio (LR) to rule-in or rule-out the disease on their own. Clinical gestalt has a positive LR between 20-50 (Trowbridge, et al., 2003). Remember that your clinical judgement trumps all other single findings.

The best use of this scan is to confirm your clinical suspicion of gallbladder disease. Gallstones are usually easily seen and can confirm your clinical diagnosis of biliary colic. If you have 2 or more findings of cholelithiasis, (such as sonographic Murphy's sign, GB wall thickening, or pericholecystic fluid), then you should call it acute cholecystitis, call a surgeon and start antibiotics. If your findings are indeterminate, or your clinical suspicion doesn't match your ultrasound findings, you should order a formal ultrasound to clarify the situation.

It's also useful to use this scan to look for this condition in the septic elderly patient with undifferentiated sepsis, as this is one of the most common causes.

Reference: Trowbridge RL, Rutkowski NK, Shojania KG. Does This Patient Have Acute Cholecystitis? *JAMA* 2003; 289 (1):80-86

Created by the UBC CPD Hands-On Ultrasound Education (HOUSE) Program (house.ubccpd.ca)

UBC CPD

CONTINUING PROFESSIONAL DEVELOPMENT
FACULTY OF MEDICINE

Rural Coordination Centre of BC

Enhancing rural health through education and advocacy